Preliminary Report of a One-Time Small-Scale Health Survey of Lake Okeechobee fish

INTRODUCTION

Anglers submitted reports (n=4) of fish with ulcers and tumor like skin lesions from Lake Okeechobee to the FWC Fish Kill Hotline mid-November 2019 through the end of January 2020. Anglers also reported lesioned fish to the FWC Division of Freshwater Fisheries Management (DFFM) group throughout 2019 prompting a joint, preliminary investigation by the FWC Fish and Wildlife Research Institute's Freshwater Fisheries Research group (FFR) and the Fish and Wildlife Health group (FWH). The sampling objective was to conduct laboratory-based pathological diagnostics in a representative portion of the fish population.

METHODS

A health survey was included as a component of routine largemouth bass population monitoring on Lake Okeechobee from January 20, 2020 through the first week of February; however, specimens evaluated in the laboratory and described here were primarily collected January 27th - 30th when health specialists could be included on field crews and promptly conduct necropsies to maximize the quality of samples.

The sampling universe was defined by a cartographic grid system and representative sites were selected randomly from numbered cells within the grid. Transects were randomly selected for each sample period.

With the exception of one redear sunfish collected by otter trawl during crappie population monitoring, sampling was conducted aboard electrofishing vessels equipped with either a VI-A-9.0 GPP or Infinity electrofisher. Electrical current was conducted through the water immediately in front of boats via two booms each with 4–8 droppers made of 1/4- to 3/8-in stainless steel cable with a pulse frequency of 60 pulses/second. For each transect, vessels tracked forward in a zigzag pattern along a length of shoreline or the edge of nearshore patches of emergent vegetation. Forward movement and shocking were continuous for 15 minutes (Bonvechio, 2017). The non-selective method stunned specimens of most fish species long enough for them to be identified from the surface and netted when appropriate. All largemouth bass and any specimens of other species with visible lesions were dipnetted and placed in a livewell while fishing was in progress. After fishing was complete at a given site, fish were measured, weighed, and examined carefully for prominent external lesions. Minor blemishes, such as a few pinpoint red foci caused by anchor worms (common copepod parasites), were expected and considered normal. Clinically healthy fish were released alive.

For the redear sunfish collected during black crappie population monitoring using an otter trawl, grids were randomly selected, and sampling began at the center of each grid. If there was wind, the trawl was towed into the wind. Otherwise, the trawl was towed in a randomly selected direction or the sampler towed the trawl in a clockwise or counterclockwise direction at 2 mph for 3 minutes. The redear sunfish was placed on ice and shipped to the FWRI laboratory. Necropsy was conducted approximately 2 days post-mortem.

Handling of lesioned specimens in the field differed depending on available resources. When health specialists were not present for collection, crews documented all lesioned specimens and killed by cold shock one representative fish for shipment on ice to St. Petersburg, for pathological evaluation (2 days postmortem). When health specialists participated in field sampling, all lesioned fish were tagged individually with a label attached to a thin wire fed in the mouth and out the branchial opening then

twisted end to end to form a secure loop without causing mechanical trauma. Tagged fish were held alive with continuous aeration for approximately 6–9 h until transported overland in the livewells of towed vessels to a mobile laboratory stationed in Okeechobee, FL. At the mobile laboratory, fish were euthanized with an overdose of tricaine methanesulfonate (Tricane S) buffered with sodium bicarbonate solution and either immediately subjected to necropsy (n=12) or placed on ice (n=6) for transport to St. Petersburg for necropsy (approximately 24 hours [n=5] and 48 hours [n=1] post mortem).

Necropsies included examination of both external and internal organs. All grossly visible lesions were documented. Some skin and gill tissues were examined by wet mount under light microscopy. Samples of lesioned tissues were fixed in 5% paraformaldehyde for routine histopathological analysis. All histological samples were embedded with paraffin medium, except for tissue from a redear sunfish, which was embedded with JB-4 plastic resin medium. Slides were stained with Mayer's Hematoxylin and Eosin (H&E), Thionin, or Periodic acid Schiff's/Metanil Yellow (PAS/MY) stains (Luna 1968; Quintero-Hunter et al. 1991). Photomicrographs of histology slides were captured with an Olympus BX51 light microscope equipped with an Olympus DP71 Digital Camera.

RESULTS

Approximately seven hundred largemouth bass (*Micropterus salmoides*) were checked for any obvious abnormalities by FFR staff between January 13th and February 7th. In addition, we cursorily examined three other species: redear sunfish (*Lepomis microphus*), gizzard shad (*Dorosoma cepedianum*), and threadfin shad (*D. petenense*). A total of 19 fish with gross abnormalities or lesions were collected between January 27th-30th from 11 sampling locations primarily around the northern periphery of Lake Okeechobee (Fig. 1). These included 16 largemouth bass, 1 gizzard shad, 1 threadfin shad, and 1 redear sunfish (Table 1). The individual fish identification number (FWH2000001, FWH2000701-718) hereafter is shown with the last three-digit numbers (e.g. 701).

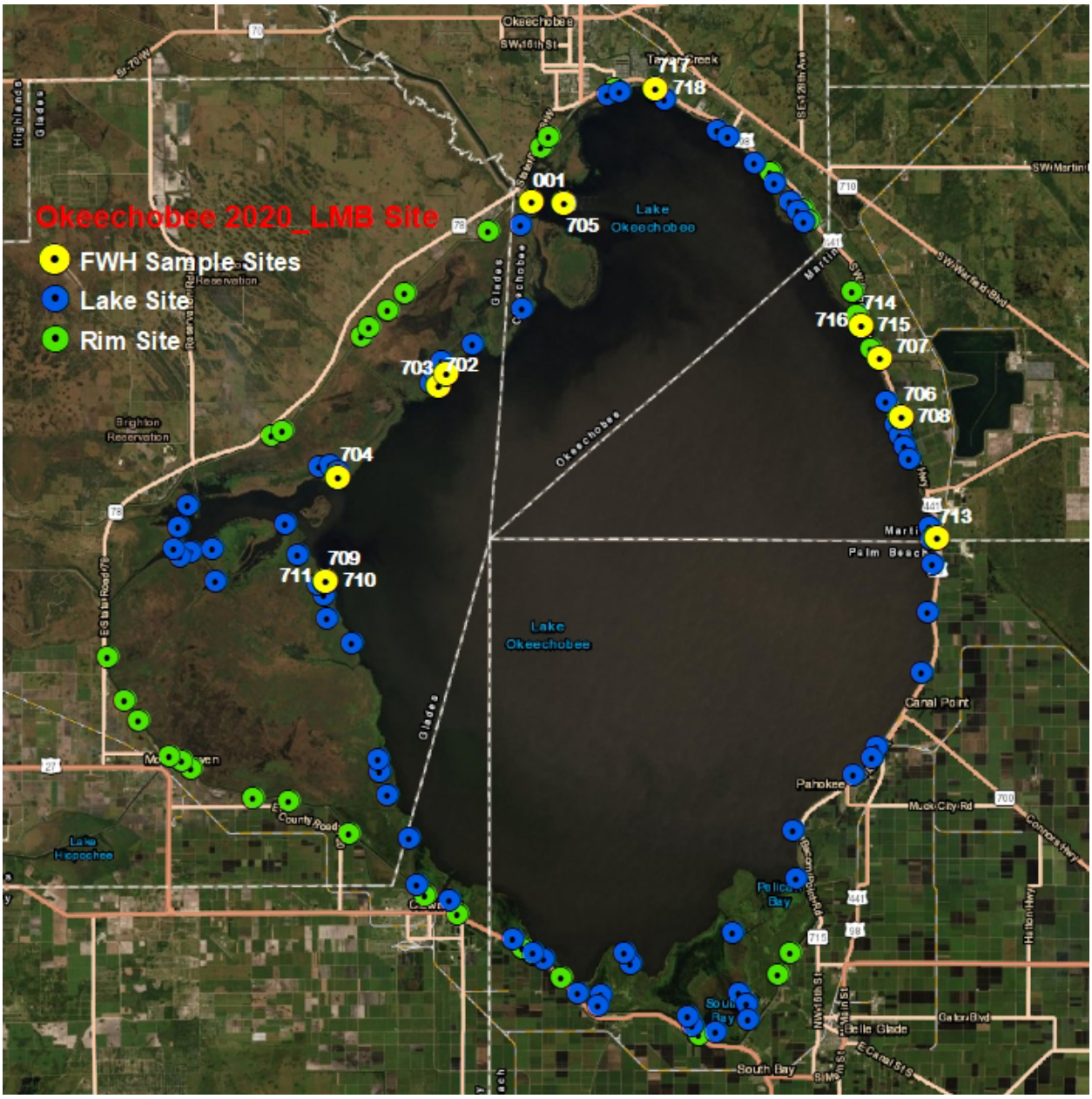

Fig. 1. Site locations for largemouth bass population monitoring surveys (green circles=rim canals, blue circles=lake proper). Yellow circles represent locations where fish with lesions were collected. No collection data was recorded for specimens 701 and 712. FWH code numbers are shown in Table 1).

Gross observations and pathology

Fish processed following initial gross health assessment presented with different conditions representing parasitic infections and other lesions (Table 1). More specifically, by tissue type (i.e. skin, gills, liver, kidney, and spleen), the following pathologies were noted:

1. Skin

Histopathological results (Table 1) are briefly classified into skin tumors (papilloma and fibroma), inflammation, degeneration (regressive reaction), and cysts (myxozoan parasites). Some of these pathologies were associated with various bacterial or parasitic infections.

A. Tumors

1. Papilloma

Papillomas were found on one redear sunfish (001) and on two largemouth bass (709 and 714); 0.3% prevalence (2/700).

The redear sunfish had grossly visible multiple nodules on the jaw skin. A tumor-like mass was attached on the upper and lower jaws of left side (**Figs. 2a and b**). The size ranged 17–27 mm diameter, and 8 mm elevation. The cut appearance was creamy red, with a soft consistency. The tissue wet mount exhibited a cauliflower-like appearance (**Fig. 2c**). The skin histology of the tumor was observed from two different areas (A and B slides). Slide A was longitudinally sectioned, and B was cross sectioned. Projections of the skin along with proliferation of altered epidermal cells (Malpighian cells) were confirmed with both slides (**Figs. 2d and e**). No mitotic figures nor inclusion bodies were found. The dermis was vascularized (**Fig. 2e**) with hemorrhagic areas sporadically found at the epidermal layer. Some areas at the epidermal layer had goblet cells (PAS positive; **Fig. 2f**). A metacercarial cyst was found in the dermis (n = 1 each on Slide A and B). The epidermis was severely necrotic, but this was very likely due to postmortem changes.

Grossly, the two largemouth bass exhibited similar skin lesions. Gelatinous discolored, raised, saddleback lesions on the trunk dorsal (size 115mm x 80mm [714]; **Fig. 3a and b**). Histopathologically, these were diagnosed as papilloma (cutaneous papilloma), a hyperplastic epidermal plaque type (**Fig. 3c**). The epidermal cell layer appeared to be proliferated with Malpighian cells (**Fig. 3d**), associated with eosinophilic granulocytic infiltration. Hemorrhage was found with necrotic erythrocytes. Scattered melanophores were observed in the epidermis; however, the melanophores were most abundant at the basement membrane adjacent to the dermis. The skeletal muscle underneath the lesioned epidermis showed nothing remarkable.

2. Fibroma

Fibromas were found in two largemouth bass (702 and 714); 0.3% prevalence (2/700). Grossly, at the lower right jaw, there was a tumor-like nodular lesion; 20 x 10 mm, with a soft consistency; under tissue wet mount, this was of a fibrous-like appearance in fish 702 (**Fig. 3e**). A similar lesion was observed in fish 714 at the lower left jaw. Histopathologically, in case 702, the mass of collagenous tissues stained unevenly, with a storiform appearance. Spindle shaped fibroblasts proliferated. Diagnosed as fibroma (**Fig. 3f**); sclerotic fibroma; or storiform collagenoma. A focal aggregation of microsporidia was also found associated with this lesion. Calcification was found in the lumen of the capillaries. Fish 714 exhibited similar pathological changes as 702 but note that this fish also possessed papilloma (see above).

B. Inflammation

Six largemouth bass (701, 704, 705, 708, 710, and 711) presented with inflammatory responses. One fish (705), grossly had a slightly raised area at the left side of trunk adjacent to the second dorsal fin. The consistency of the nodule had both hard and soft areas. A minimally reddened area was found. Cut appearance revealed reddened tissue, with necrosis in the skeletal muscle of a confined area (**Fig. 4a**). A presumptive chronic response was suspected during the necropsy. Under the tissue wet mount, a granuloma and bright blue pigments were confirmed. Histopathologically, the following was noted: Severe granulomatous inflammation associated with bacterial infection (small, rods [presumptive *Aeromonas hydrophila* complex], and large bacillus-like types) and other microorganisms observed as masses of spores localized at the center core of the granuloma in the skeletal muscle (**Fig. 4b and c**). This center core was filled with necrotic skeletal muscle (**Fig. 4c**), cholesterol cleft, and possible iron pigments presumably from dead erythrocytes. Macrophage aggregates and leukocytic infiltrates surrounded the granuloma periphery. Skin tissue above the granuloma in the skeletal muscle showed nothing remarkable. However, the skeletal muscle adjacent to the granuloma and separated by the myosepta border was degenerated. Additional diagnostics should include Gram and Prussian blue stains for confirmation of bacteria and iron pigments, respectively.

The remaining five largemouth bass (701, 704, 708, 710, and 711), grossly had discolored reddening (**Fig. 5a**). Under the skin tissue wet mount, diverse parasitic organisms, such as nematodes, stalked ciliates [**Fig. 5b**] and anchor worms (*Lernaea*; **Fig. 5g**), as well as fungal hyphae were confirmed. Among these, two (708 and 711) had anchor worms to which were attached a large number of stalked ciliates as confirmed by tissue wet mount (hyperparasitism; **Fig. 5g**).

Histopathologically, all six largemouth bass had dermatitis (**Fig. 4d**) associated with possible multinucleated giant cells (or presumptive osteoclasts), and hemorrhages. A portion of the skin tissue was eroded, and focal granulomatous inflammation was found in the dermis of one largemouth bass (708). Presumably the inflammatory responses were targeted against these parasitic organisms. This was confirmed in histologic section with stalked ciliates on the epidermis (**Fig. 5c and d**) associated with bacteria in one fish (704).

One largemouth bass (706) also had an anchor worm on the left flank above the pelvic fin confirmed with wet mount. The lesion consisted of a raised, reddened, 10mm x 7 mm center with a puncture-like wound necrosis (**Fig. 6a**) with a bad odor. The skeletal muscle was degenerated, hemorrhagic, and leukocytes infiltrated (myositis).

The gizzard shad (712) grossly exhibited a raised ulcerative area (10 mm x 10 mm) just anterior to the caudal peduncle and left flank above the anus (20mm x 55 mm). A leech was found attached to the skin tissue. Under the skin tissue wet mount, copepods and other unidentifiable parasites were confirmed. Histopathologically, at the dermis, a granulomatous inflammation was confirmed with the center core severely necrotic and associated with degraded traces of possible fungal hyphae. This was provisionally diagnosed as ulcerative mycosis (UM).

The threadfin shad's (713) fin rays appeared to be necrotic with an infection of short rod bacteria associated with dermatitis.

C. Degeneration

Two largemouth bass (703 and 717) exhibited degenerative tissue changes. Grossly, fish 703 (**Fig. 6b**) had 20mm x 18mm focus of scale loss and white coloration at the right flank. Under a skin tissue wet mount, a light infection of *Trichodina* was found. For fish 717, a small ulcerative lesion (6 x 7 mm) was found on the lower left side flank behind and ventral to the pectoral fin (**Fig. 6c**). Histopathologically, on fish 703, a focal area of skin erosion was found. Multinucleated giant cells (or possible osteoclasts) were found in the dermis underneath the scale. The skeletal muscle tissue had degenerated (granular degeneration). For fish 717, severe dermal necrosis, especially underneath the scale pocket, was found. This could be due to postmortem changes. However, the epidermis above the dermal necrotic area showed nothing remarkable. Some portion of the skin epidermis exhibited ulceration. Focally, myositis was found.

D. Cysts

One largemouth bass (707) had a grossly visible tumor-like nodule (7 mm x 6 mm, elevation 4 mm) on the caudal peduncle (**Fig. 4e**). The consistency was hard. Under a skin tissue wet mount, mature cysts were found filled with myxozoa (possibly *Myxobolus*) spores.

2. Gills

Brief summary results of gross pathological changes as well as tissue wet mount observations of the gill tissue can be found in Table 2.

Grossly, four largemouth bass (702, 703, 704, and 706) had focal to multifocally missing gill filaments associated with necrosis. Under tissue wet mounts, granulomatous inflammation (703) and telangiectasia (706) were confirmed. Histopathologically, hyperemia was confirmed at the filament (central venous sinus) and lamellae in these three specimens. Telangiectasia was confirmed at the lamellae (704; **Fig. 5e**). In one specimen (703), filaments were also slightly hyperplastic, with leukocytic infiltrates (lymphocytes and eosinophilic granulocytes; branchitis). In these specimens, necrotic lesioned filaments were not observed histologically. The granulomas detected during tissue wet mount exams (702 and 703) were not confirmed histologically, presumably, because the targeted lesion areas were missed in the sectioned slides. Light infections of parasitic monogeneans (**Fig. 5f**) were confirmed in four specimens (702, 703, 706, and 709).

3. Liver, spleen, and kidney

Brief summary results of gross pathological changes in the liver, spleen, and kidney (posterior portion) tissues can be found in Table 3.

Grossly, during necropsy, the internal organs were observed with white cysts, or white spots, a nodular surface appearance, discoloration, and paleness (Table 3). Histopathologically, for all largemouth bass, all spleens and livers, except for two fish (714 and 717), and all the kidneys except for one fish (714) had infections by the digenetic trematode (**Fig. 5h**) known as white grub (*Posthodiplostomum minimum*).

One largemouth bass spleen (704) had a large cyst with presumptive lipid in the center. Multifocal necrotic areas were found surrounding the large cyst. Possibly this could be due to a host cellular

response to the white grub, especially as these parasites (N = 8) occupied a large area of the sectioned splenic tissue (706 & 716).

The kidney of three largemouth bass (705, 706, and 709) had multifocal, leukocytic infiltrates in the hematopoietic tissue (nephritis). Focal necrosis of hematopoietic tissue found in one fish (714). The area stained lightly pink with Thionin stain –suggestive of a possible bacterial infection.

In largemouth bass, granulomatous inflammation was confirmed in three spleen samples (705, 709, 714), and one liver (706). In the hepatic parenchyma, altered foci (**Fig. 5i**) were found centrilobularly (717). Possible iron pigments were found throughout the hepatic parenchyma (this would need Prussian blue stain confirmation; 704). Hepatocytes were hypertrophied (709). Splenic cells were necrotic (709). The spleen of 717, had focus of possible bacterial infection found at the serosa with no signs of a host response. Thus, possible postmortem contamination had occurred. Note that postmortem artifacts were confirmed in samples taken 1 d after fish's death (714 liver and spleen, 716 spleen and kidney, and 717 spleen and kidney).

DISCUSSION AND RECOMMENDATIONS

Disease and parasitic infections are natural and expected processes in healthy fish populations and their presence alone provides no information about ecosystem health; however, substantial changes in their prevalence and mean intensity can indicate problems, many of which can be mitigated if causative factors are identified. Disease comes in many forms, and some types of lesions can provide clues about etiology. Thus, successful management depends on recognition of unusual temporal and spatial trends in disease prevalence, identification of disease etiologies, and the development of strategies to address indicated causes.

The work summarized in this report represents preliminary steps toward these ends in the management of Lake Okeechobee. There were no previously existing efforts to monitor fish disease in the lake, but anecdotal reports by anglers were considered enough justification to commit resources to investigation. On a very limited temporal and spatial scale, we reconnoitered the occurrence of fish disease and collected pathological data to support meaningful interpretation of our field observations. Most observed lesions were minor and of little or no cause for concern, but a few cases could suggest further investigation is warranted.

This type of research by FWC has previously resulted in effective management solutions. For example, an FWC investigation was launched in the late 1990s when increased numbers of fish in the St. Lucie and Caloosahatchee rivers were observed by the public to have severe skin ulcers. Pathological evaluations of affected fish by FWC health specialists revealed intense infections by the oomycete fungus, *Aphanomyces invadans*, which causes the disease known as ulcerative mycosis (UM; Sosa et al. 2007). This pathogen is always present in the environment, but outbreaks of UM can be triggered by environmental factors that promote infections. In this case dramatic releases of high volumes of freshwater from Lake Okeechobee into the estuarine reach of the rivers led to a rapid decrease in salinity that likely stressed fish and promoted transmission by the low salinity tolerant oomycete fungus. Based on FWC research and recommendations, a multi-agency team was able to provide input to the ACOE into the way in which water releases were conducted, and in following years, pulsed releases with smaller volumes of freshwater released over a longer period of time allowed the fish to acclimate to the necessary salinity drop. This resulted in fewer UM incidences (FWC, unpublished data; Sime 2005).

As is the case here, to draw meaningful conclusions from health surveys, it is important to distinguish between parasitic infections and diseases like UM. The former are normal and very common, while the latter, differentiated by significant impairment of the host, are not expected to occur at high prevalence under good conditions. In the present survey, many fish with insignificant lesions caused by parasites were scored as healthy and released, while some of these returned to the lab for further investigation were arguably not severe enough to be considered signs of significant impairment. Still, some parasitic infections were at least noteworthy and might be indicators of stressful conditions if they were found at a higher density or more frequently in a larger sample of the population. Gill monogeneans and protists (*Trichodina* and myxozoa), and skin lesions associated with the anchor worm (*Lernaea*), as well as multi-organ infections by the digenean white grub, have commonly been reported in largemouth bass (Mueller 1937; Rawson & Rogers 1972; Timmons & Hemstreet, 1980; Noga 1986, Grizzle & Goldsby 1996). The stalked ciliates (e.g., *Epistylis* sp. or *Heteropolaria* sp.) are also known parasites of Florida fish, but these along with *Aeromonas* bacteria, can cause a condition known as red sore disease (Hazen et al. 1978; Huizinga et al. 1979; Reed and Francis-Floyd, 2011). The occurrence of red sore disease in largemouth bass has been attributed to physiological stress and increased temperature (Esch et al. 1976; Huizinga et al. 1979). Without further study, it is not possible to determine if this condition is more prevalent in Lake Okeechobee fish than would normally be expected nor determine possible contributing environmental factors.

Cutaneous tumors (papillomas and fibromas) were also among the lesions observed during this survey, and typically these should occur at very low prevalence in fish populations. Based on gross appearance, tissue wet mounts, and histopathological observations, three fish (one red ear and two largemouth bass) had cutaneous lesions diagnosed as papillomas. These are benign tumors (Blazer et al. 2007). Further study e.g., by transmission electron microscopy may reveal more detail about a possible viral etiology. It should also be mentioned here that one of the largemouth bass with a tumor-like nodule in fact had a cyst caused by a myxozoan parasite. These visibly obvious cysts can easily be misdiagnosed as tumors and can be misinterpreted by the public as cause for alarm. It is important to stress that proper diagnostics should be conducted by trained professionals to ensure correct interpretation about the health status of fish in Lake Okeechobee.

If temporally and spatially comprehensive studies revealed that lesions reported in this study were more common than would be expected in Lake Okeechobee fish populations, many potential stressors would need to be considered. Lake Okeechobee has a well-documented history of water management, chronic cyanobacteria blooms, water quality issues, eutrophication, and pollutant inputs from agrochemicals, contaminants, and herbicide treatments to scale back invasive macrovegetation such as *Hydrilla* (Canfield & Hoyer, 1988; Heinz et al., 1991, Walker & Havens, 1995; Ogburn et al. 1996; Spalding et al. 1997; Burger et al., 2004; Engstrom et al. 2006). All of these factors, singly or synergistically, acute or chronic, can potentially stress fish, could be directly toxic, or could lead to a range of fish disease conditions. In particular, Lake Okeechobee has a history of chronic cyanobacteria blooms that produce microcystins (Havens et al., 2016; Rosen et al. 2017), known hepatotoxins that are also tumor promoters. Microcystins can have a range of sub-lethal effects on fish (Malbrouck and Kestemont, 2006) and could potentially be one of a number of factors in the Lake that could contribute to impaired fish health.

Of relevance to this study was the possible implication of herbicide usage in the increased appearance of benign (papillomas) and malignant (carcinomas) skin cancers in fish in Central Florida lakes in the 1970s.

Harshbarger & Clark (1990) documented 35 cases of epidermal papillomas and squamous carcinomas in two bullhead species in lakes in Polk County, and commented on possible environmental linkages with over 50 pesticides being used in citrus groves at that time, as well as spraying with diquat, paraquat, and 2,4-D to kill water hyacinth (*Eichhornia crassipes*). Cutaneous papillomas in fish have been reported globally, with high prevalence in benthic species such as bullhead being causally connected with exposure to carcinogenic contaminants (Baumann et al. 1996), or chlorinated wastewater effluent (Grizzle et al. 1984).

In summary, the diverse skin lesions and other conditions observed during this small, one-time survey include both parasitic infections and tumors, and the prevalence, not the presence, of these lesions should be the focus. So, more spatially and temporally comprehensive surveys will be necessary to identify concerns. Further, fish in Lake Okeechobee are exposed to a milieu of anthropogenic stressors, and careful pathological evaluation of lesions is necessary to identify which, if any of these should be more closely studied as likely contributing factors. Some observed lesions, particularly tumors, have been previously linked to anthropogenic factors, but interpretation is based on limited evidence and could be misleading without more data and knowledge about environmental co-factors that could potentially play a direct or indirect role in affecting fish health.

22 April 2020

Report prepared by Yasu Kiryu, Jan H. Landsberg, Theresa T. Cody, and Micah Bakenhaster
Field sampling and necropsies conducted by Freshwater Fisheries Research and Fish and Wildlife Health staff – Micah Bakenhaster, Theresa Cody, Yasu Kiryu, and Adam Richardson
Histology conducted by Noretta Perry, Patrick Wilson, Yvonne Waters, and Michelle Franco
Fish and Wildlife Health Program,
Fish and Wildlife Research Institute,
Florida Fish and Wildlife Conservation Commission,
100 Eighth Avenue SE,
St. Petersburg, FL 33701-5095

Table 1. Summary of redear sunfish (RES), largemouth bass (LMB), gizzard shad (GS), and threadfin shad (TS) collected from Lake Okeechobee during 15–30 January 2020 that exhibited skin lesions. Details of descriptive findings of the skin lesion, skin wet mount, and histological diagnosis are found in the text. Figure numbers used in the text also listed.

Specimen #	Common name	Date collected	Post-exam (d)	Fish handling	Skin lesion gross brief descriptions	Skin wet mount brief findings	Diagnosis (histological)	Figure #
FWH2000001	RES	1/15	2	on-ice	Nodule at jaw	Cauliflower-like appearance	Papilloma	2a–f
FWH2000701	LMB	1/27	0	on-ice	Focal discoloration, reddened trunk	Possible nematode	Inflammation	
FWH2000702	LMB	1/27	0	euthanasia	Nodule at jaw	Fibrous-like appearance	Fibroma	3e, f
FWH2000703	LMB	1/27	0	euthanasia	Focal discoloration at trunk	*Trichodina*	Degeneration	6b
FWH2000704	LMB	1/27	0	euthanasia	Multifocal reddening at trunk	Stalked ciliates	Inflammation	5a, c, d
FWH2000705	LMB	1/28	0	on-ice	Nodule at trunk	Granuloma and pigments	Inflammation	4a–c
FWH2000706	LMB	1/28	0	euthanasia	Puncture-like wound at trunk	Anchor worm (*Lernaea*)	inconclusive	6a
FWH2000707	LMB	1/28	0	euthanasia	Nodule at peduncle	Myxozoa (mature cysts)	NA	4e
FWH2000708	LMB	1/28	0	euthanasia	Ulcerated at caudal peduncle	Anchor worm, stalked ciliates	Inflammation	
FWH2000709	LMB	1/29	0	euthanasia	Gelatinous discolored dorsal	Not examined	Papilloma	
FWH2000710	LMB	1/29	0	euthanasia	Focal discoloration, reddened trunk	Fungal hyphae	Inflammation	4d
FWH2000711	LMB	1/29	2?	euthanasia, on-ice	Focal discoloration, reddened trunk	Anchor worm	Inflammation	5b, g
FWH2000712	GS	1/29	0	euthanasia, on-ice	Ulcerated, raised, above anus	Copepod, leech	Ulcerative mycosis (UM)	
FWH2000713	TS	1/29	2?	euthanasia, on-ice	Not recorded	Not examined	Bacterial infection	
FWH2000714	LMB	1/30	1	on-ice	Gelatinous discolored dorsal lower left jaw (33 x 10 mm)	Melanin pigments Not examined	Papilloma Fibroma	3a–d
FWH2000715	LMB	1/30	1	on-ice	Eye injury	Possible fish fin in the eye	Poor slides	
FWH2000716	LMB	1/30	1	on-ice	Ulcerous on lower left jaw	Hyphae	No slides	
FWH2000717	LMB	1/30	1	on-ice	Focal, ulcerative, reddening at ventral	Erythrocytes	Degeneration	6c
FWH2000718	LMB	1/30	1	on-ice	Hemorrhagic inflammation at jaw	Not examined	No slides	

Table 2. Summary of largemouth bass (LMB) collected from Lake Okeechobee during 27–29 January 2020 that exhibited with gill lesions. Details of histopathological findings of the gill are found in the text. Figure numbers used in the text also listed.

Specimen #	Common Name	Date Collected	Post-exam (d)	Fish handling	Gill gross brief descriptions	Gill wet mount brief findings	Gill histopathology	Figure #
FWH2000702	LMB	1/27	0	euthanasia	Necrosis	Granuloma	Monogeneans	
FWH2000703	LMB	1/27	0	euthanasia	Necrosis	Granuloma, monogeneans	Hyperplasia, hyperemic, branchitis	
FWH2000704	LMB	1/27	0	euthanasia	Necrosis	Not examined	Hyperemia, telangiectasia	5e
FWH2000706	LMB	1/28	0	euthanasia	Necrosis	Telangiectasia, monogeneans	Hyperemia	
FWH2000709	LMB	1/29	0	euthanasia	Normal	Not examined	Monogeneans	5f

Table 3. Summary of largemouth bass (LMB) collected from Lake Okeechobee during 27–30 January 2020 for the internal soft tissues (liver, spleen, and kidney). Brief gross findings of the organs shown. Detail histopathological findings are found in the text. Figure numbers used in the text also listed.

Specimen #	Common Name	Date Collected	Post-exam (d)	Fish handling	Liver gross brief descriptions	Spleen gross brief findings	Kidney gross brief findings	Figure #
FWH2000704	LMB	1/27	0	euthanasia	Nodular surface	Focal discoloration	No samples	
FWH2000705	LMB	1/28	0	on-ice	Atrophied	Discolored	White cysts	
FWH2000706	LMB	1/28	0	euthanasia	White cysts	White cysts	No record	
FWH2000709	LMB	1/29	0	euthanasia	White spots	No record	White spots	5h
FWH2000714	LMB	1/30	1	on-ice	Normal	Normal	Normal	
FWH2000716	LMB	1/30	1	on-ice	Pale	Normal	White spots	
FWH2000717	LMB	1/30	1	on-ice	Normal	Normal	Normal	5i

REFERENCES

Blazer, V. S., Fournie, J. W., Wolf, J. C. & Wolfe, M. J. 2007. Manual for the microscopic diagnosis of proliferative liver and skin lesions in the brown bullhead *(Ameiurus nebulosus*). Pennsylvania Sea Grant. http://citeseerx.ist.psu.edu/viewdoc/download?doi=10/1.1.140.7084&rep=rep1&type=pdf

Bonvechio, K. 2017. Standardized Sampling Manual for Lentic Systems. Version 6, September 26, 2017. Florida Fish and Wildlife Conservation Commission. Tallahassee, FL.

Burger, J., Orlando, E.F., Gochfield, M. Bincxik, G.A. & Guillette, L.J. 2004. Metal Levels in Tissues of Florida Gar (*Lepisosteus Platyrhincus*) from Lake Okeechobee. *Environ. Monitor Assess.* 90: 187–201

Canfield Jr., D.E. & Hoyer, M.V. 1988. The Eutrophication of Lake Okeechobee. *Lake and Res. Manage.* 4: 91-99, DOI: 10.1080/07438148809354817

Engstrom, D. R., Schottler, S.P., Leavitt, P.R. & Havens, K. E. 2006. A reevaluation of the cultural eutrophication of Lake Okeechobee using multiproxy sediment records. *Ecol. Appl.* 16: 1194–1206.

Esch, G. W., Hazen, T. C., Dimock, Jr R. V., Gibbons, J. W. 1976. Thermal effluent and the epizootiology of the ciliate *Epistylis* and the bacterium *Aeromonas* in association with centrarchid fish. *Trans. Am. Microsc. Soc*. 95: 687–693.

Grizzle, J. M. & Goldsby, M. T. 1996. White grub *Posthodiplostomum minimum centrarchi* metacercariae in the liver of largemouth bass: quantification and effects on health. *J. Aquat. Anim. Health* 8: 70–74.

Grizzle, J. M., Melius, P. & Strength, D. R. 1984. Papillomas on fish exposed to chlorinated wastewater effluent. *J. Natl. Cancer Inst*. 73: 1133–1142.

Harshbarger, J. C. & Clark, J.B. 1990. Epizootiology of neoplasms in bony fish of North America*. Sci*. *Total Environ*. 94: 1–32.

Havens, K., Paerl, H., Phlips, E., Zhu, M., Beaver, J., and Srifa, A. 2016. Extreme weather events and climate variability provide a lens to how shallow lakes may respond to climate change. *Water* 8, 229. doi:10.3390/w8060229

Hazen, T.C., Raker, M.L., Esch, G.W. & Fliermans, C.B. 1978. Ultrastructure of red-sore lesions on largemouth bass (*Micropterus salmoides*): Association of the ciliate *Epistylis* sp. and the bacterium *Aeromonas hydrophila*. *J. Protozool*. 25: 351–355.

Heinz, G.H., Percival, H.F., & Jennings, M.L. 1991. Contaminants in American alligator eggs from Lake Apopka, Lake Griffin, and Lake Okeechobee, Florida. *Environ Monitor Assess*. 16: 277–285.

Huizinga, H. W., Esch, G. W. & Hazen, T. C. 1979. Histopathology of red-sore disease (*Aeromonas hydrophila*) in naturally and experimentally infected largemouth bass *Micropterus salmoides* (Lacepede). *J. Fish. Dis.* 2: 263–277.

Luna, L. G. 1968. Manual of histologic staining methods of the Armed Forces Institutes of Pathology, 3rd edition. McGraw-Hill, New York.

Malbrouck, C., and Kestemont, P. 2006. Effects of microcystins on fish. *Environ Toxicol Chem* 25(1)**,** 72–86.

Mueller, J. F. 1937. Some species of *Trichodina* (Ciliata) from freshwater fishes. *Trans. Am. Microsc. Soc.* 56: 177–184.

Noga, E. J. 1986. The importance of *Lernaea cruciata* (Le Sueur) in the initiation of skin lesions in largemouth bass, *Micropterus salmoides* (Lacepede), in the Chowan River, North Carolina, USA. *J. Fish. Dis.* 9: 295–302.

Ogburn III, R.W., Hanlon, C., Gong, S.W. & Broughton, E. 1996. Compliance with water quality criteria in a multiple-use lake, Lake Okeechobee, Florida. *Lake and Res. Manage*. 12: 371–380.

Quintero-Hunter, I., Grier, H. & Muscato, M. 1991. Enhancement of histological detail using metanil yellow as a counterstain in periodic acid Schiff's hematoxylin staining of glycol methacrylate tissue sections. *Biotech. Histochem.* 66: 169–172.

Rawson, M.V. & Rogers, W. A. 1972. The seasonal abundance of the Ancyrocephalinae (Monogenea) on largemouth bass in Walter F. George Reservoir. *Proc. Helminthol. Soc. Wash*. 39: 159–162.

Rosen, B.H., Davis, T.W., Gobler, C.J., Kramer, B.J. & Loftin, K.A. 2017. Cyanobacteria of the 2016 Lake Okeechobee and Okeechobee Waterway harmful algal bloom. Open-File Report, USGS, Reston, VA.

Reed, P. and Francis-Floyd, R. 2011. "Red Sore Disease" in Game Fish. University of Florida/IFAS Extension publication. VM85, 1-3.

Sime, P. 2005. St. Lucie Estuary and Indian River Lagoon conceptual ecological model. *Wetlands* 25: 898–907.

Spalding, M. G., Steible, C.K., Sundlof, S.F. & Forrester, D. J. 1997. Metal and organochlorine contaminants in tissues of nestling wading birds (Ciconiiformes) from southern Florida. *Florida Field Nat.* 25: 42-50.

Timmons, T. J. & Hemstreet, W.G. 1980. Prevalence rate of *Lernaea cyprinacea* L. (Copepoda: Lernaeidae) on young-of-the year largemouth bass, *Micropterus salmoides* (Lacepede), in West Point Reservoir, Alabama-Georgia, USA. *J. Fish. Dis*. 3: 529–530.

Walker Jr, W.W. & Havens, K.E. 1995. Relating algal bloom frequencies to phosphorus concentrations in Lake Okeechobee. *Lake and Res. Manage*. 11: 77–83.

FIGURE CAPTIONS

Fig. 2. (a) Redear sunfish (*Lepomis microlophus*), FWH2000001 with nodular masses (arrow heads) on the upper and lower jaws. (b) Higher magnification of (a) with the nodular masses (arrow heads) mostly located at left side of upper and lower jaws. (c) Skin wet mount with cauliflower-like appearance (circled). (d) Cross to tangentially sectioned of the skin nodule histology with projection appearance (H&E prepared with JB4 resin; Slide B). (e) High power view of proliferated epithelial (M = Malpighian) cells, some goblet cells located at epidermis (arrow heads), and vascularized dermis (V) found (H&E prepared with JB4 resin; Slide A). (f) Same sectioned area of (e) stained with Periodic acid Schiff's, showing goblet cells (arrow heads) with positive reaction (PAS-MY prepared with JB4 resin).

Fig. 3. (a) Largemouth bass, FWH2000714. Dotted circle at the skin exhibited with gelatinous, raised, plaque-like lesion (b) Closeup of (a) at the dotted circle area. (c) Skin histology of fish (a) at the dotted circled area. E=epidermis; D=dermis; S=scale. Note that epidermal layer is thickened, and invaginated (H&E). (d) Higher magnification of (c) shown with the Malpighian cells (M) proliferated, diagnosed as papilloma (H&E). (e) Largemouth bass, FWH2000702, shown with nodule at the jaw. (f) Histology of the nodular lesion show in (e), proliferated with fibroblasts, diagnosed with fibroma (H&E).

Fig. 4. (a) Largemouth bass, FWH2000705, nodular lesion with cut appearance. (b) Histology of skin and muscle tissue of fish (a) shown with the center core of granulomatous inflammation including short rod bacteria (arrow heads) and possible spore producing microorganisms (dotted circle) (H&E). (c) Same histology tissue sectioned area of (b) shown with bacillus-like larger bacteria (arrow heads) and the skeletal muscle necrosis (NM) (H&E). (d) Histology of skin epidermis exhibiting inflammation and possible giant cells (FWH2000710) (H&E) (e) Nodule located at the caudal peduncle (arrowhead) appeared to be myxozoan infection, confirmed with tissue wet mount observation (FWH2000707).

Fig. 5. (a) Largemouth bass, FWH2000704; reddening (dotted circled) of the skin found. (b) Stalked ciliates found in skin tissue wet mount (FWH2000711) (Nomarski optics) (c) Skin histology of fish (a) at the dotted circled area show with stalked ciliate (dotted circle) infection; E = epidermis of skin. Note that the parasitic infected area of the skin tissue is eroded (H&E) (d) close-up of stalked ciliate shown in (c) with bacterial mass attached to the stalk portion (arrowheads). (e) Gill histology of fish (a) with telangiectasia (ballooning; arrowheads) at the lamellae (L). (H&E) (f) Gill histology shown with monogenean parasite (arrowhead) found between lamellae (L), attached to the filament (F) (FWH2000709) (H&E). (g) Tissue wet mount observation shown anchor worm (FWH2000711) hyperparasitized with stalked ciliates (arrowhead). (h) Histology of the liver tissue infected with digenetic trematode, white grub (FWH2000709) (H&E). (i) Histology of the liver showing altered focus (FWH2000717) (H&E).

Fig. 6. (a) Largemouth bass, FWH2000706; Puncture wound-like area (dotted circle) found on the trunk latera. (b) Largemouth bass, FWH2000703; focal discoloration (dotted circled) of the skin at the trunk. (c) Largemouth bass, FWH2000717; focal ulcerative reddening (dotted circle) found on the ventral skin.

Figure 2.

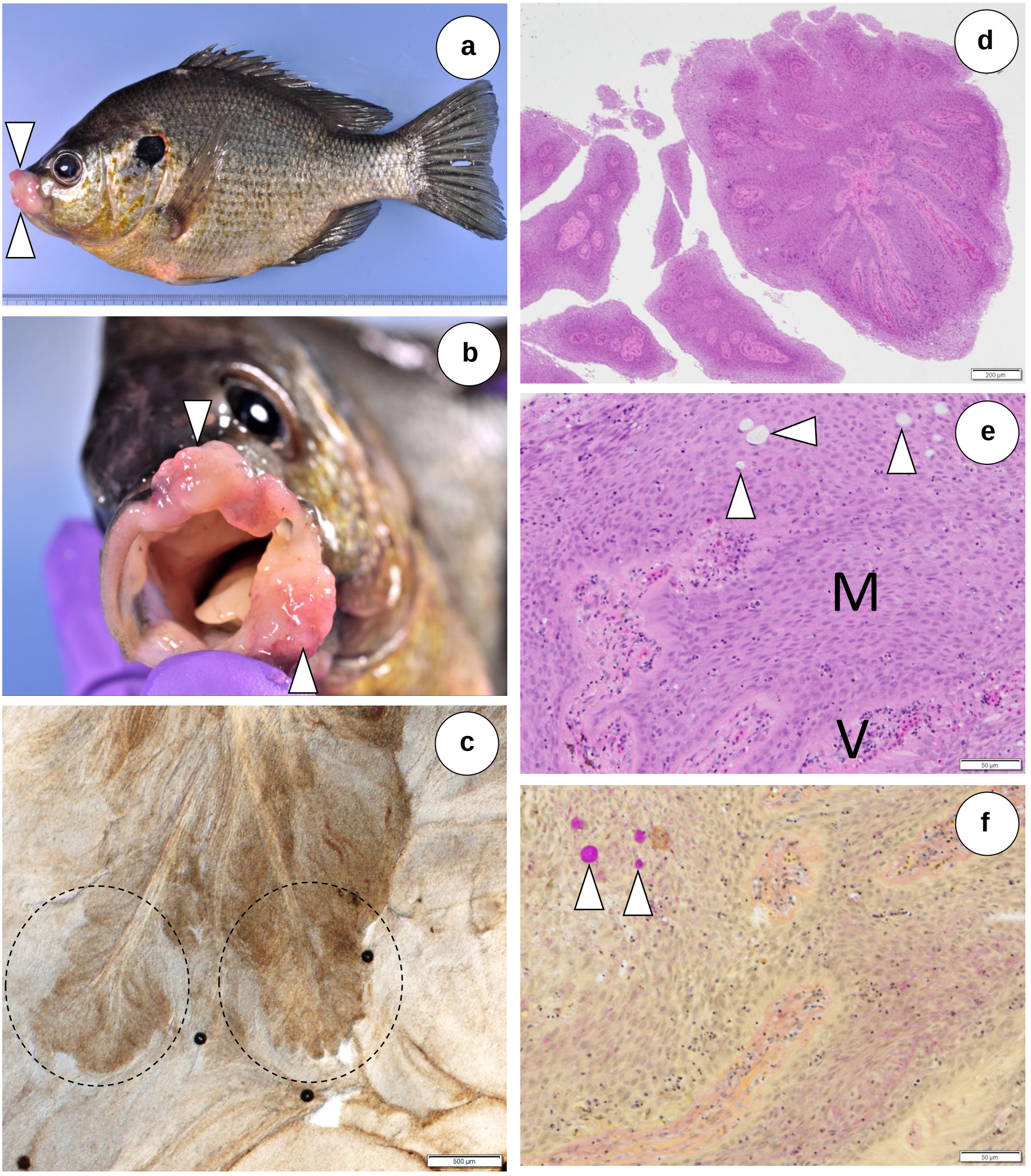

Figure 3.

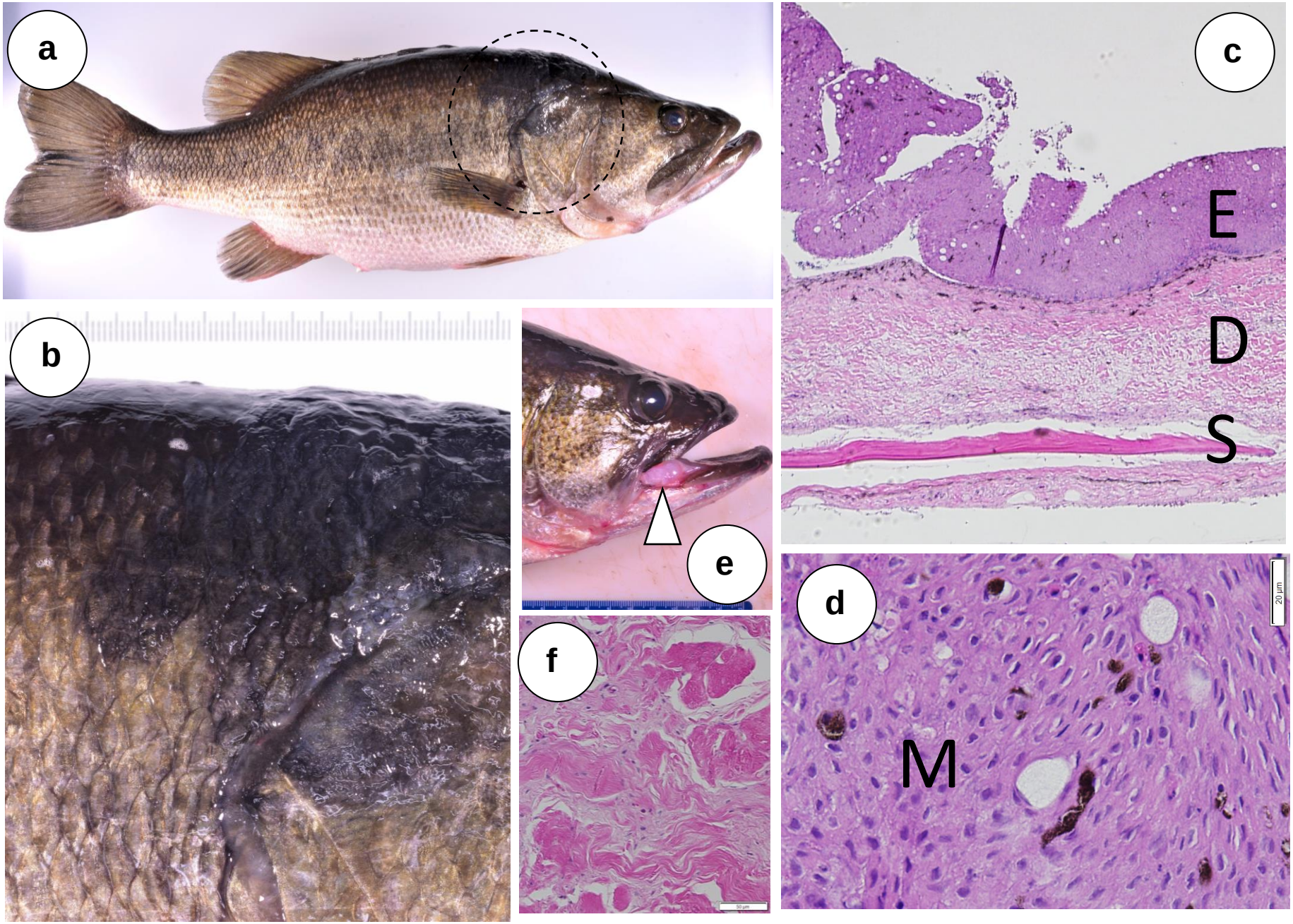

Figure 4.

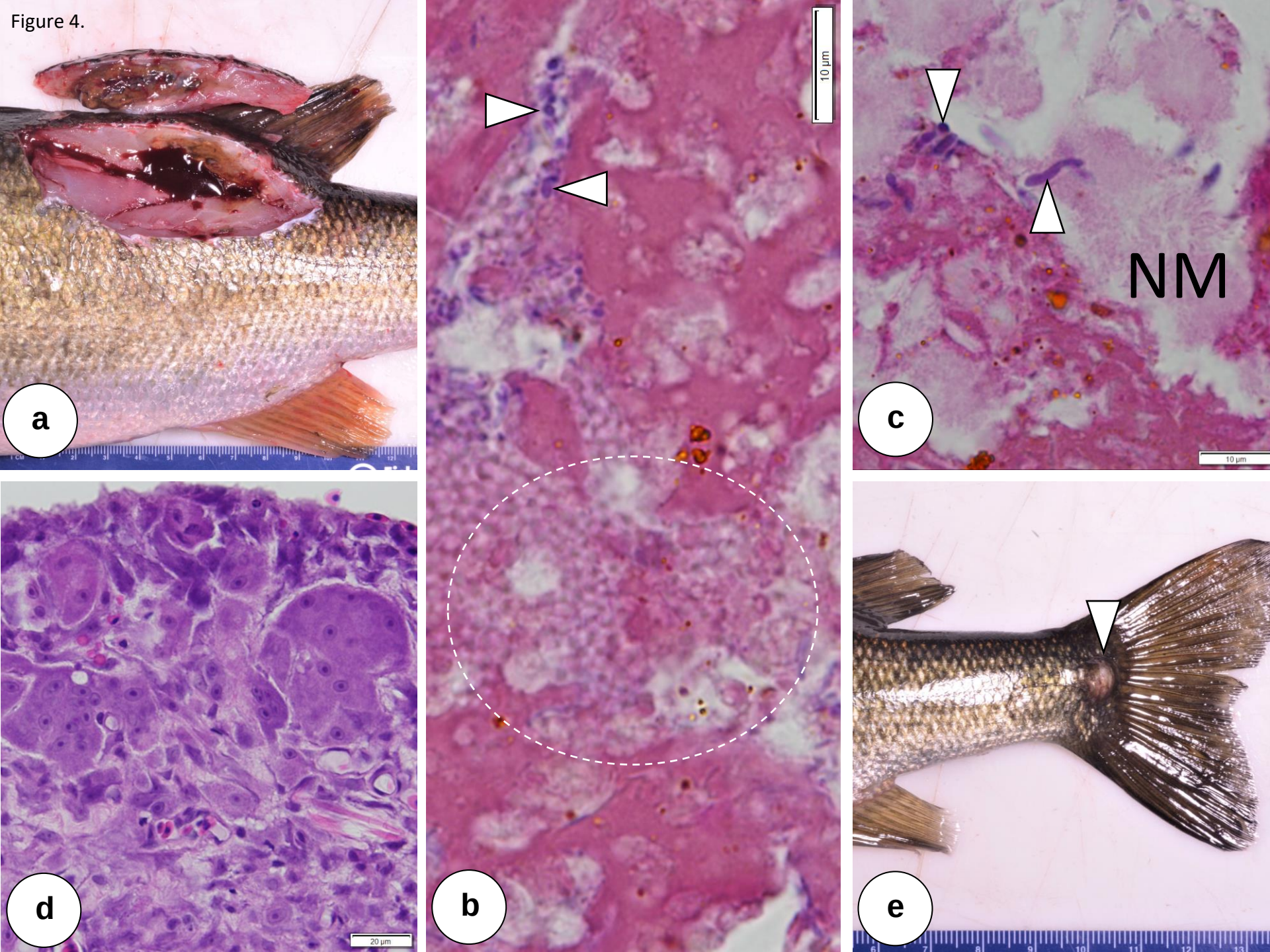

Figure 5.

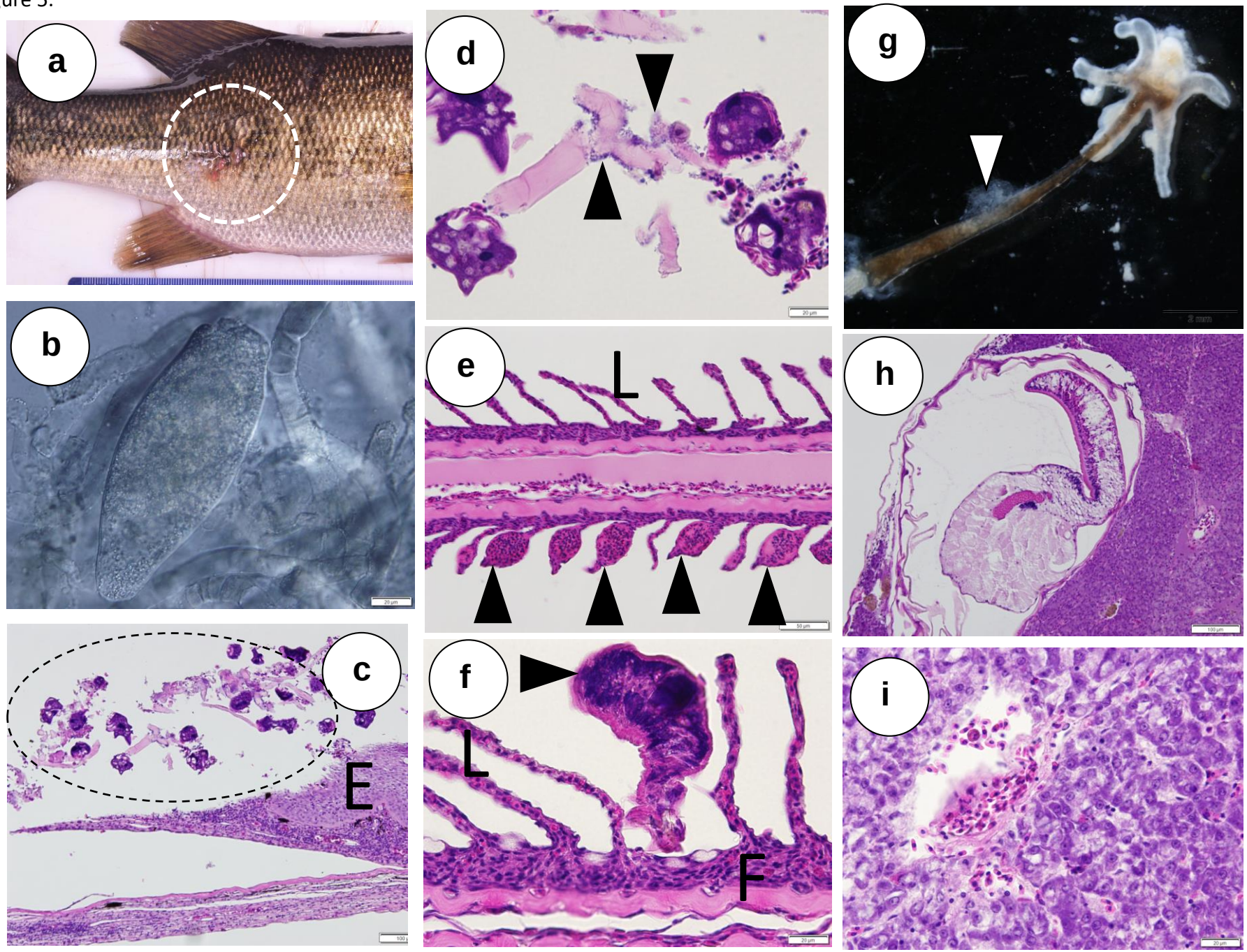

Figure 6.